

Gastroprotective Effect of *Leptadenia Hastata* (Pers.) Decne and Histopathological Changes on Indomethacin-Induced Gastric Ulcer in Rats

Isaac John Umaru^{1,2}, Fasihuddin A. Badruddin¹ and Hauwa A. Umaru³

¹Faculty of Resource Science and Technology, University of Malaysia Sarawak, Kuching, 94300 Kota Samarahan Malaysia

²Department of Biochemistry, Federal university wukari, Taraba State

³Department of Biochemistry, Modibo Adama Federal University Technology Adamawa State

*Corresponding Author E-mail: isaac.j62@yahoo.com

Received: 13.08.2018 | Revised: 29.09.2018 | Accepted: 5.10.2018

ABSTRACT

Objectives: Ulcer induced rats has been largely investigated, but gastro protective effect of *Leptadenia hastata* (Pers.) Decne and histopathological changes on indomethacin-induced gastric ulcer in rats was lacking thus, the ulcer score and percentage protection was calculated from the stomach and histopathological study of the ulcer stomach was performed. **Material and Method:** The effect of methanol root extract were studied in 40 albino rats over a period of 21 days, the rats were divided into eight groups, those in group one served as the control, group two as the negative control (Indomethacin), group three as the positive control (Omeprazole) and group four to eight are dosed ranged groups from 100-500mg/kg extract. Tissue injury and its infiltration were examined and scored, the length and breadth of the lesion were measured for ulcer index. **Results:** Inflammatory and fibrosis alteration were present in ulcer treated rats, at days 21 colonic wall thickening and fibrotic remodelling were evident as well as blood vessels remodelling. The percentage rate of healing was 87.23% at 500ppm, 62.11% at 400ppm, 52.34% at 300ppm and 32.77% at 200ppm when compared to the control (93.60%). The present findings provide an integrated view of ulcer healing processes occurring in the ulcer induced colonic compartment of rats induced by indomethacin. These ulcerogenic alteration may represent a suitable basis for understanding the effects of *Leptadenia hastata* Methanol crude extract to ulcer treatment.

Key words: *Leptadenia hastata*, Histopathology, Indomethacin, Haematoxylin, Eosin, Omeprazole.

INTRODUCTION

The World Health Organization estimates that 80% of the world's inhabitants rely mainly on traditional medicines for their health care. Many medicinal plants have proved to successfully aid in various ailments leading to mass screening for their therapeutic

components. Today, the search for Medicinal plant rich in wound healing and antimicrobial properties is escalating due to their medicinal importance in controlling many related chronic disorders such as ulcer, cancer and diabetic diseases¹.

Cite this article: Umaru, I. J., Fasihuddin, A., Badruddin and Hauwa, A., Umaru, Gastroprotective Effect of *Leptadenia Hastata* (Pers.) Decne and Histopathological Changes on Indomethacin-Induced Gastric Ulcer in Rats, *Int. J. Pure App. Biosci.* 6(5): 20-27 (2018). doi: <http://dx.doi.org/10.18782/2320-7051.6792>

Leptadenia hastata is widely distributed throughout the world. This plant species is used in various applications especially for medicinal purposes. They are significant element of the world cultural heritage; they resort for treating health problems¹. It is typically grown in tropical dry lands in sandy soil. Wild foods like this plant provide food security during seasonal changes and are used medicinally in many areas. The plant belongs to many of the root-type famine-food plants, they are drought tolerant and can stay in the soil intact for a long time.

The vernacular names for *Leptadenia hastata* include; hagalhadjar in Arabic and in Chad, yadiya in Hausa in Nigeria and Niger, while in kusumehayla in Ethiopia, ekamongo from Turkana in Kenya, Moore people call it lolongo in Burkina Faso, tarhat or darhat from Wolof in busumba, amata from Jola in Senegal, and Bambara's call it nzongne in Mali². Local healers use the plant for hypertension, catarrh and skin diseases³. The breeders commonly used the leaf and stems for the treatment of parasites and against placental retention among their animals^{4,5}.

It is widely used in the treatment and management of diverse disease and ailment. Despite being one of the well-known medicinal plants used around the world for their traditional medicine, studies regarding the pharmacological properties of *Leptadenia hastata* are very rare. *Leptadenia hastata* root extract has so far not been screened for anti-ulcer activity. Hence, we evaluate the anti-ulcer effects of *Leptadenia hastata* Methanol root extract in the present investigation using Albino rats as animal models.

Ulcer is the erosion in the lining of the stomach or duodenum and is caused by the disruptions of the gastric mucosal defence and repair systems⁶. However, the gastrointestinal tract is more susceptible to toxic chemical exposure which may execute the chronic inflammation, and later, it becomes tumour in the gastrointestinal tract⁷ Thus, Ulcer in the stomach is called gastric ulcer and in the duodenum, is called duodenal ulcer and

together peptic ulcer. Gastric hyperacidity and ulcer are very common disease among young and old today. It is an imbalance between damaging factors within the lumen and protective mechanisms within the gastro duodenal mucosa. However prolonged anxiety, haemorrhagic surgical shock, emotional stress, trauma, and burns were the known cause to severe gastric irritation⁸. It is one of the most prevalent gastro intestinal disorders commonly faced by many around the world these days. Treatments available for these disease is generally non-specific and is aimed at reducing the production of gastric acid and re-enforcing gastric mucosal protection such as food, adequate rest and avoidance of ulcerogenic agents such as coffee, alcohol, tobacco and some NSAID drugs etc.

The drugs used in the treatment of ulcer are, receptor blockers, proton pump inhibitors, drugs affecting the mucosal barrier and act on the central nervous system⁹. Even though a range of drugs are available for the treatment of ulcers, many of these do not satisfy all the requirements and have side effects^{10,11}.

Inflammation is seen in such condition. It is believed that controlling inflammation may help to alleviate these conditions but the classical description of inflammation accounts for the increases in the number of leucocytes and a variety of complex mediator molecule¹². Traditionally, the treatment for inflammation has been to use a Non-Steroidal Anti-Inflammatory Drug (NSAID), such as aspirin, for pain relief and to use corticosteroids or even disease-modifying drugs to reduce other symptoms of the disease. It was also reported that hexane Leaf extract shows a good potential as having an ulcer healing properties¹³. This was in line with the aim of this study, to determine the antiulcer potential of the methanol extract of the roots of *Leptadenia hastata* using Indomethacin Induction.

MATERIAL AND METHODS

Plant material: Freshly leaves of *Leptadenia hastata* were collected from the uncultivated

farm land of the Federal University Wukari Taraba State, Nigeria and was authenticated at Ahmadu Bello University Zaria and Voucher No PU: 2 ABU Herbarium No 900220. The plant *Leptadenia hastata* (yadiya) was dried under room temperature.

Preparation of plant material:

The plant *Leptadenia hastata* were washed with distilled water to remove the soil and dust particles they were thoroughly air dried and powdered using laboratory grinder machine (FGR-350, Quest Scientific) extraction using methanol by placing 150g of the powdered samples into an Erlenmeyer flask and methanol three times the weight of the extracts was added, the solution was covered and shaken at an interval of an hour and then allowed at room temperature to stand for 7days, the mixture were then filtered using what man filter paper No.4 and the solvent was evaporated using a rotary evaporator (Heidolph Laborato 400) under reduced pressure below 50EC. It was then stored under a frozen condition until required.

Breeding of animals (Albino rats):

Forty male albino rats weighing between (150-190g) were obtained from the animal farm, National Research Institute Vom, Jos Plateau State Nigeria. They were put in cages at room

temperature (20-27°C) under 12/12 night/dark. They were maintained on a standard animal pellets (vital feeds, Grands cereals and oil meal Jos) and water ad libitum. All the experiment was conducted based on the approval of the Animal and Research ethical committee.

Chemical and reference drug:

All chemicals used in this investigation were of analytical grade and were obtained from SIGMA

Omeprazole (reference drug) was obtained from a pharmacy shop in yola Adamawa State, Nigeria. The drug is an anti-ulcer drug which blocks the enzymes in the wall of the stomach from producing acid, the main culprit in peptic ulcer. By blocking the enzymes, the production of stomach acid is decreased, thus allowing the ulcer to heal¹⁴.

Experimental protocol:

The albino rats were randomly divided into eight groups, this include normal group, negative and positive control group while five groups for extracts dosage, except the normal all the groups were induced with ulcer, the animals were starved from food 24hours and water 2hours before the commencement of the experiment.

- . Group 1: Normal control (diet/water)
- . Group 2: Rats (induced ulcer indomethacin 25mg/kg/bwt +diet /water)
- . Group 3: Rats (induced ulcer indomethacin 25mg/kg/bwt +diet/water + Omeprazole)
- . Group 4: Rats (induced ulcer indomethacin 25mg/kg/bwt +diet /water +100mg/kg/bwt extracts)
- . Group 5: Rats (induced ulcer indomethacin 25mg/kg/bwt +diet /water +200mg/kg/bwt extracts)
- . Group 6: Rats (induced ulcer indomethacin 25mg/kg/bwt +diet /water +300mg/kg/bwt extracts)
- . Group 7: Rats (induced ulcer indomethacin 25mg/kg/bwt +diet /water +400mg/kg/bwt extracts)
- . Group 8: Rats (induced ulcer indomethacin 25mg/kg/bwt +diet /water +500mg/kg/bwt extracts)

Determination of ulcer lesion:

The drug Indomethacin (IND), a common non-steroidal anti-inflammatory drug (NSAID)¹⁵, was administered intragastrical via the aid of an orogastric cannula. Four hours later, the rats were sacrificed using chloroform anaesthesia; the stomach was removed and opened along the greater curvature. The tissue was fix with 10% formaldehyde in saline, microscopic examination was carried out and scored the

presence of lesion using the method of Nwafor et al¹⁶ with minor modifications. Animals were divided into eight groups of 5 rats each that had fasted for 24 h prior to receiving an oral dose of saline, (Omeprazole, 20 mg/kg) and extract of *Leptadenia hastata* (100, 200, 300,400 and 500 mg/kg). After 50 min, groups 2 to 8 were orally treated with 25mg/kg/bwt of indomethacin for gastric-ulcer induction. Animals were killed 1 h after the

administration of ethanol and the stomachs excised. The extents of lesions were measured in form of Ulcer Area (UA). The lengths of ulcer on the gastric mucosa were measured using a plane square ruler.

The Ulcer Area (UA) was calculated. The percentage (%) of protection (P%) availed to the animals through the various treatments were calculated using the formula:

$$P\% = \frac{(\text{UA ulcer control} - \text{UA treatment})}{\text{UA ulcer control}} \times 100$$

Histopathology:

The stomach Histopathology of all the animals were fixed in 10% buffered formalin in labelled bottles and processed routinely for histology examination. The tissue embedded in

paraffin wax were sectioned in 5µm thick, stained with Haematoxylin and eosin, mounted on glass slides and then examined under a standard light microscope.

Haematoxylin/eosin

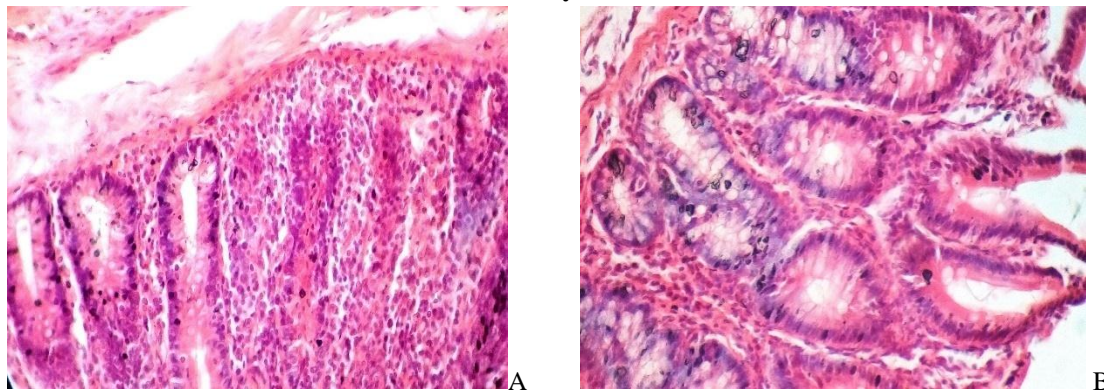


Fig 1: Control before induced by indomethacin

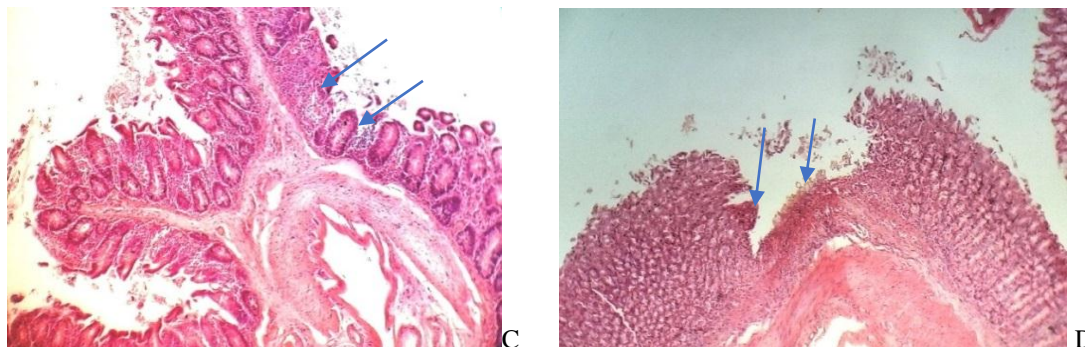


Fig 2: After induced by indomethacin

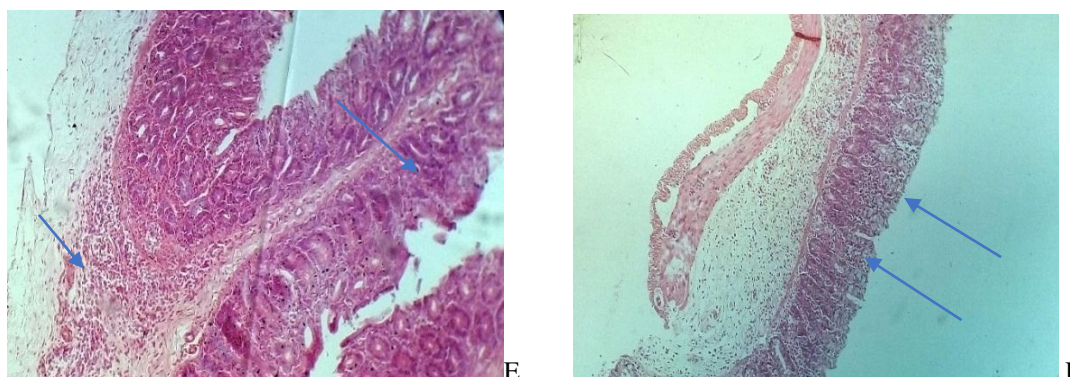


Fig 3: After 21 days' post treatment

Fig. 1 Histological appearance of haematoxylin/eosin-stained full-thickness colonic samples in control rats (A and B), and Fig 2: Animals with indomethacin induced (C and D). The colonic wall of controls shows normal morphological features (A), with compact cells (B). Colonic specimens from rats with damaged cells (C and D). The cells appear to be vacuolized and altered (arrows),

and Fig 3: Infiltrated by eosinophil granulocytes (E and F arrow heads) At day 21.

Statistical analysis

Result were expressed as mean SD. Statistically significance was determined by one-way analysis of variance (one-way ANOVA) at $P < 0.05$ was considered significant.

Table 1: Effect of methanol root Extracts of *Leptadenia hastata* on indomethacin induced ulcer

Group	Treatment/Dose (mg/kg/bwt)	Ulcer indices	Rats Weights	Protection (%)
Group A	-	-	-	-
Group B (-ve)	25	2.93±0.70	151.65 ± 8.49	0.00
Group C (+ve)	20	0.11±0.05 ^a	154.05 ± 10.47	93.60%
Group D	100	2.67±0.46 ^a	154.92 ± 6.48	14.89%
Group E	200	2.02±0.68 ^a	161.89 ± 10.87 ^c	32.77%
Group F	300	1.53±0.28 ^a	157.36 ± 8.06 ^c	52.34%
Group G	400	1.20±0.52 ^a	161.89 ± 12.03 ^c	62.11%
Group H	500	0.75±0.21 ^{ab}	154.37 ± 7.40	87.23%

Values are Mean ± SD (n = 5)

Significantly ($p > 0.05$) decreased compared to negative control

RESULT AND DISCUSSION

From the Table, the effect of the extract in group D-His significant when compared with group C that received the standard drug and this shows increased gastro-protective effect as the dose increases table 1. The Table shows the inhibitory effect of the extract and indomethacin, the highest percentage inhibition of ulcer lesion was produced by the reference drug Omeprazole at 20mg/kg/bwt followed by the extract at 500 mg/kg/bwt in group H, thus showing that at higher doses of the extract, the percentage inhibition would be higher than the drug. The evaluation of the experimental rats shows a significant decrease in body weight and Microscopic damage of the colon at 151.65 ± 8.49 when compared to the control 154.05 ± 10.47 likewise at day 21, the body weight gain was moderate increased in comparison with the control to shows a drift towards a recovery as compared with indomethacin (negative control). As shown in fig 1 cell deposition within the whole colonic wall increased significantly at day 21 displaying thickened collagen fibres deposition.

The defence mechanism of the gastro-intestinal mucosa against aggressive factors such as HCl, bile acid and NSAIDS, mainly consists of functional, humoral and neuronal factors¹⁷. Peptic ulcers are common disorder of the entire gastrointestinal tract that occurs mainly in the stomach and the proximal duodenum¹⁸. The various animal models for peptic ulcers have played a significant role in the elucidation of the peptic ulceration¹⁹. since ulcer is a multi-factorial disease, its treatment faces great difficulties due to the limited effectiveness and severe side effects of the currently available drugs¹⁸. owing to the side effects of the available drugs, many plant derived natural products have been evaluated as therapeutics for the treatment of a variety of diseases, including the peptic ulcer^{20, 21}. Indomethacin is one of the ulcerogenic agents that induce intense damage in gastric mucosa by promoting disturbances in the mucosal microcirculation, ischemia and appearance of free radicals, endothelin release, degranulation of mast cells, inhibition of prostaglandins and decrease in gastric mucus production¹⁷.

The methanol extract of the leaf of *Leptadenia hastata* as presented on the table (100, 200, 300, 400 and 500 mg/kg/bwt) and Omeprazole (20 mg/kg, drug control) significantly inhibited ulcer formation in this model by 14.89, 32.77, 52.34, 62.11, and 87.23%, respectively. The reduction of the lesions seen with the methanol extract of *Leptadenia hastata* suggests that part of the protective mechanism could involve mucosal defensive factors. Gastric mucosal damage caused by indomethacin and other related non-steroidal anti-inflammatory drugs which result from the inhibition of prostaglandins synthesis via the arachidonic pathway^{22,23}. Prostaglandins serve protective functions in the stomach by maintaining gastric microcirculation^{22, 23} and causing gastric secretion of bicarbonate²⁴ and mucus. Thus, the effect of the extract in this study suggests, it may possess cytoprotective action probably by enhancing prostaglandin synthesis. The extract significantly ($p < 0.05$) protected gastric mucosa against indomethacin challenge. Indomethacin - induced gastric mucosal lesions, predominant in the glandular part of the stomach, are caused by the direct toxic action of ethanol, reduction of the secretion of bicarbonate and depletion of gastric wall mucus²⁵.

It was reported by Robert *et al.*,²⁶ that Agents that enhance mucosal defensive factors inhibit agents of induced gastric mucosal lesions. This is in conformity with our earlier suggestion that *Leptadenia hastata* extract may owe its anti-ulcer effect to cytoprotection probably due to enhancement of prostaglandins synthesis. Although the precise mechanism of cytoprotection remains to be elucidated, the level of protection offered by the extract against indomethacin induced ulcers directly suggests it may enhance prostaglandins synthesis.

The plant *Leptadenia hastata* methanol crude extract contains many polar phytochemicals including flavonoids and other polyphenols¹⁷. The presence of polyphenols-flavonoids may be contributory to the anti-ulcerogenic property observed in this experiment. Polyphenols and flavonoids may prevent ulcer

development due to their protein precipitating and vasoconstriction effects²⁷. Their astringent action can help in precipitating micro proteins on the ulcer site, thereby forming an impervious layer over the lining that hinders gut secretions and protects the underlying mucosa from toxins and other irritants²⁸.

This propensity to bind with proteins also explains the fact that polyphenols inhibit enzymes responsible for acid secretions in the stomach thus offered gastro protection observed.

CONCLUSION

This result therefore suggests that the plant extract of *Leptadenia hastata* contain significant anti-ulcer activity in animal model. It has muco-protective activity and gastric anti-secretory when compared with that of the reference drug Omeprazole. The anti-ulcer activity is probably due to the presence of flavonoids and some phytochemicals present. Efforts are ongoing to characterize and explore the biological activity of the contributory compounds present in the extract in University Malaysia Sarawak.

AUTHORS CONTRIBUTION

The research work was done by Isaac John Umaru under the supervision of Fasihuddin Ahmed Badruddin, Hauwa A Umaru helped with proof reading and plant extraction.

CONFLICT OF INTERESTS

We declare that we have no conflict of interest.

Acknowledgements

The authors are thankful to the Natural Product laboratory FRST/FSTS University Malaysia Sarawak for the enabling support to carry out this study.

REFERENCES

1. Sarkiyayi, S., Onche, H. O., Anti-Inflammatory and Analgesic Effect of *Leptadenia hastata* on Albino Rats. *Am Jnl of Biochem* 5(2): 35-41 (2015).

2. Thomas, S. D., *Leptadenia hastata*: A Review of its traditional uses and its pharmacological Activity. *Med. Chem* **2**: 148-150 (2012).
3. Dambatta, S. H., Aliyu, B. S., A survey of major ethno medicinal plants of Kano north, Nigeria, their knowledge and uses by traditional healers. *Bayero Journal of Pure and Applied Sciences*. **4(2)**: 28-34 (2011).
4. Bayala, B., Telefo, P. B., Bassole, I. H., Tamboura, H. H., Belemtougri, R. G., Sawadogo, L., Malpoux, B., Dacheux, J. L., Anti-spermatogenic activity of *Leptadenia hastata* (Pers.) Decne leaf stems aqueous extracts in male wistar rats. *Jnl of Pharmacol and Toxicol*. **6(4)**: 391-9 (2011).
5. Arbonnier, M., Arbres, Arbustes et Lianes des Zones Sèches d'Afrique de l'Ouest. 1st Edn, CIRAD Publishers, Paris 538-541 (2002).
6. Grossman, M. I., Peptic Ulcer: A Guide for the Practicing Physician. Year Book Medical Publisher, Chicago. pp: 179, ISBN: 0815140096 (1981).
7. Bera, S., Das, B., Arnab, D., Preventive effect of *Cycas revoluta* in 1, 2-dimethylhydrazine-induced colon cancer in wistar rat model. *Asian J Pharm Clin Res*. **11(5)**: 120-123 (2018).
8. Rao, C. V., Sairam, K. and Goel, R. K., Experimental evaluation of *Bacopamonniera* on rat gastric ulceration and secretion. *Indian J. Physiol. Pharmacol*. **44**: 35-41 (2000).
9. Manonmani, S., Viswanathan, V. P., Subramanian, S. and Govindasamy, S., Biochemical studies on the antiulcerogenic activity of canvery 100, an Ayurveda formulation in experimental ulcers. *Ind. J. Pharmacol*. **27**: 101-105 (1995).
10. Anoop, A. and Jegadeesan, M., Biochemical studies on the antiulceration potential of *hemidesmus indicus R. Br. Var. Indicus*. *J. Ethnopharmacol*. **84**: 149-156 (2003).
11. Dharmani, P., Mishra, P. K., Maurya, R., Chauhan, V. S., and Palit, G., *Allophylusserratus*: A plant with potential anti-ulcerogenic activity. *Journal Ethnopharmacol*. **99**: 361-366 (2005).
12. Mautri, P. and Witiak, D. T., Inhibition of cyclooxygenase and 5-lipoxygenase. *Curr. Med. Chem*. **1**: 328-355 (1994).
13. Zahra, M. A. S. F., Mahmood, A. A., Hapipah, M. A., Suzita, M. N. and Salmah, I., Anti-ulcerogenic activity of aqueous extract of *Ficus deltoidea* against ethanol-induced gastric mucosal injury in rats. *Res. J. Med. Sci.*, **3(2)**: 42-46 (2009).
14. Isaac, J. U., Fasihuddin, A. B., Zaini, B. A., Effect of *Leptadenia hastata* hexane leaf extracts against haematological, biochemical and indomethacin induced ulcer in rats. *European Journal of Pharmaceutical and Medical Research*. **5(5)**: 35-41 (2018).
15. Niamprem, P., Spinivas, S. P., Tyaboonchai, W., Development and characterization of indomethacin-loaded muco-adhesive nanostructured lipid carriers for topical ocular delivery. *International Journal of Applied Pharmaceutics* **10(2)**: 91-96 (2018).
16. Nwafor, P. A., Effrain, K. D. and Jack, T. W., Gastroprotective effects of aqueous extract of activity of aqueous extract of *ficus deltoidea* against ethanol-induced gastric mucosal injury in rats. *Res. J. Med. Sci.*, **3(2)**: 42-46 (1996).
17. Omale, J., Elejo, B. O., Okpachi, C. A. and Moses, O. T., Anti-ulcerogenic and Anti-inflammatory Activity of *Cissus multistriata* Extract in Experimental Animals. *British Journal of Pharmacology and Toxicology* **4(3)**: 74-79 (2013).
18. Mota, K. S., Dias, G. E., Pinto, M. N., Luiz-Ferreira, A., Souza-Brito, A. R., Hiruma-Lima, C. A., Barbosa Filho, J. M. and Batista, L. M., Flavonoids with gastro protective activity. *Molecules*. **14(3)**: 979-1012 (2009).
19. Lee, A., Animal models of gastroduodenal ulcer disease: *Baillieres best pract. Res. Clint. Gastroenterol*. **14(1)**: 75-96 (2000).
20. Desousafakao, H., Leite, J. A., Barbosa-Filho, J. M., Athayde-Filho, P. F.,

- DeoliveiraChaves, M. C., Moura, M. D., Ferreira, A. L., De Almeida, A. B., Souza-Brito, A. R., De Fatima FormigaMeloDinez, M. and Batizta, L. M., Gastric and duodenal antiulcer activity of alkaloids: A review. *Molecules*. **13(12)**: 3198-3223 (2008).
21. Musthaba, M., Baboota, S., Athar, T. M., Thajudeen, K.Y., Ahmed, S. and Ali, J., Patented herbal formulation and their therapeutic applications. *Recent Pat. Drug Deliv. Formula*. **4(3)**: 231-244 (2010).
22. Vane, J. R., Inhibition of prostaglandin synthesis as a mechanism of action of aspirin like drugs. *Nat. N. Boil*, **231**: 232-235 (1971).
23. Ferreira, S. J. and Vane, J. R., New aspects of the mode of Action of NSAIDS. *Ann. Rev. Pharmacol*. **14**: 57-70 (1974).
24. Garner, A., Flemstrom, G. and Healing, J. R., Effects anti-inflammatory agents and prostaglandins on aad and bicarbonate secretions in the amphibian isolated gastric mucosa. *Gastroenterology*. **77**: 451-457 (1979).
25. Marhuend, E., Martin, M. J. and Lalastra, C. A. D., Anti-acrogenic activity of *Aescine* in different experimental models. *Phytother Res*. **7**: 13-16 (1993).
26. Robert, A. J., Nezamis, E., Lancaster, C. and Hanchar, A. J., Cytoprotection by gastric necrosis produced by alcohol, HCl, NaOH, hypertonic NaCl and thermal injury. *Gastroenterology*. **77**: 433-443 (1979).
27. Aguwa, C. N., Nwako, S. O., Preliminary studies of the root extracts of *Nauclealatifolia* Smith, for anti-ulcer properties. *Niger J Pharm Sci*. **4**: 16-23 (1988).
28. Nwafor, P. A., Okwuasaba, F. K., Binda, L. G., Antidiarrhoeal and antiulcerogenic effects of methanolic extract of *Asparagus pubescens* root in rats. *Journal of Ethnopharmacology*. Oct **1**: **72(3)**: 421-427 (2000).